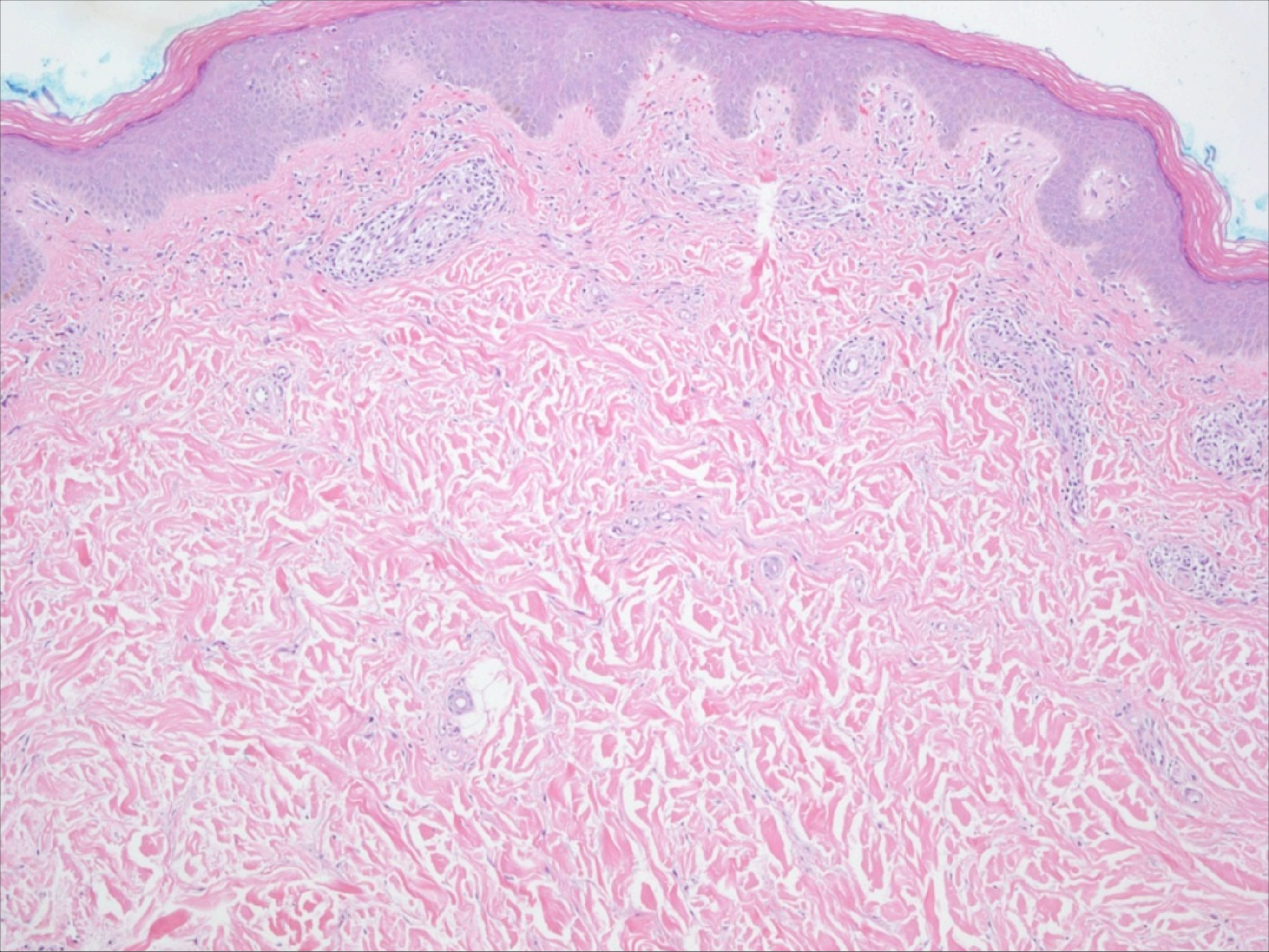
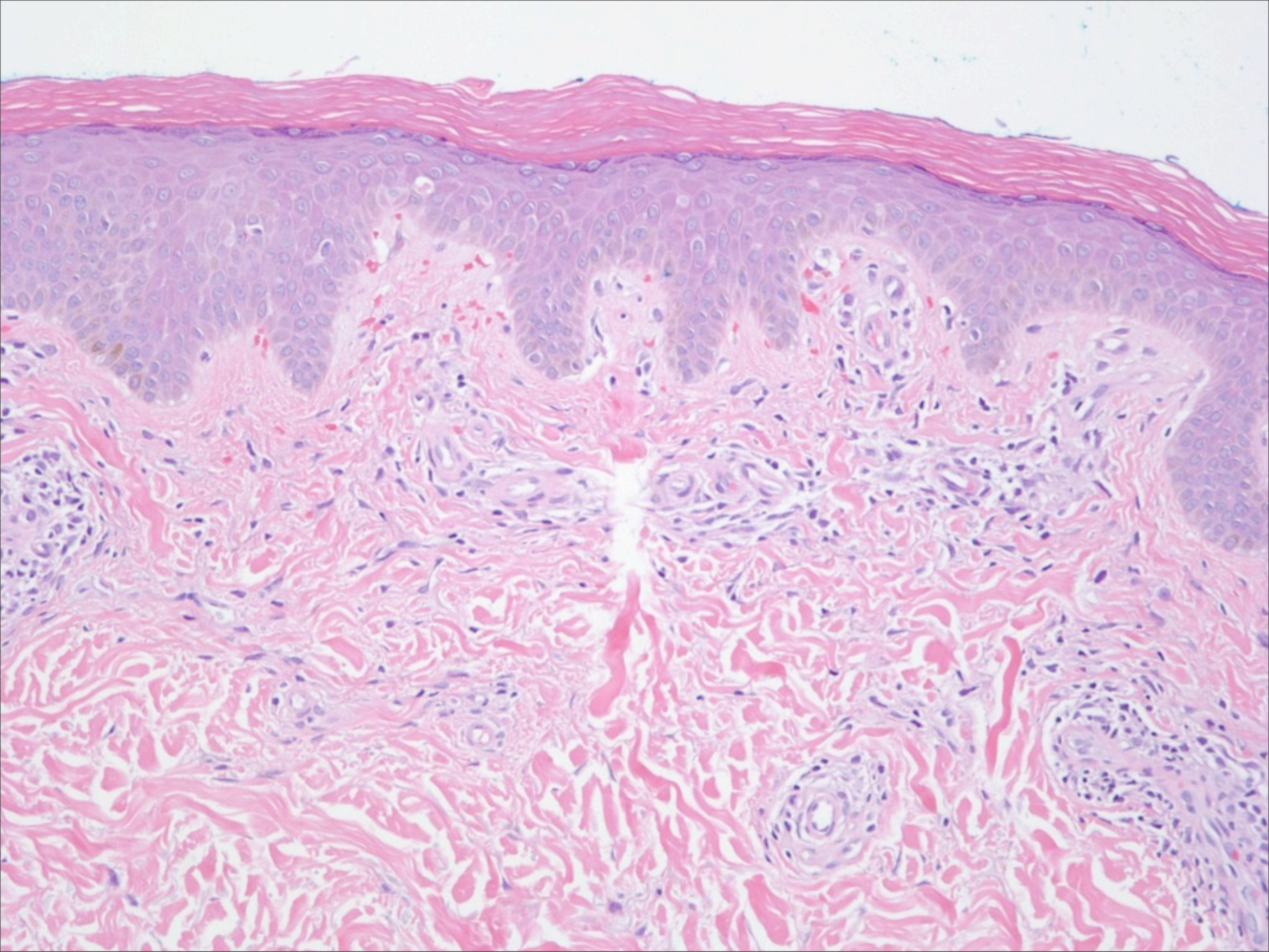
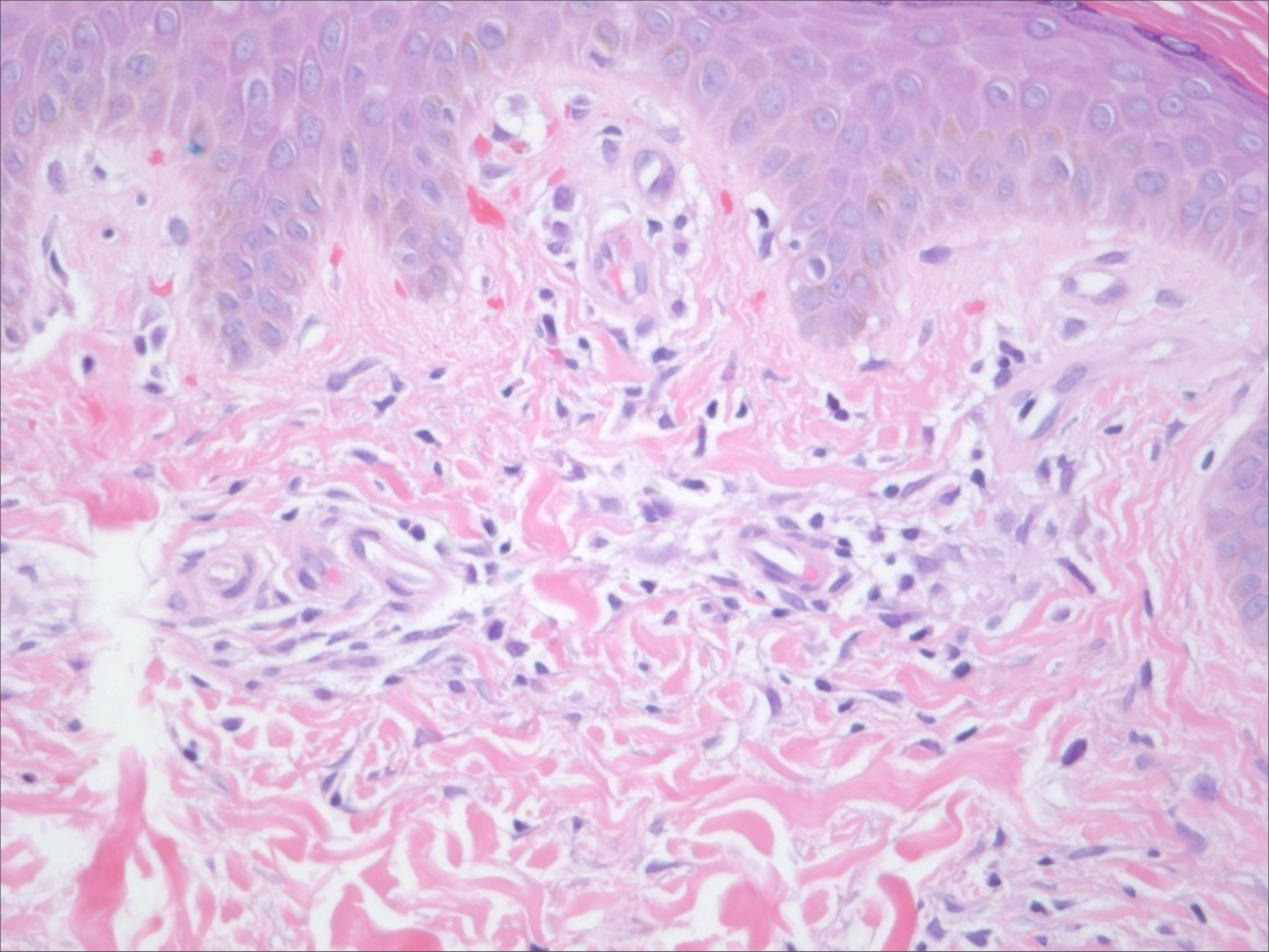

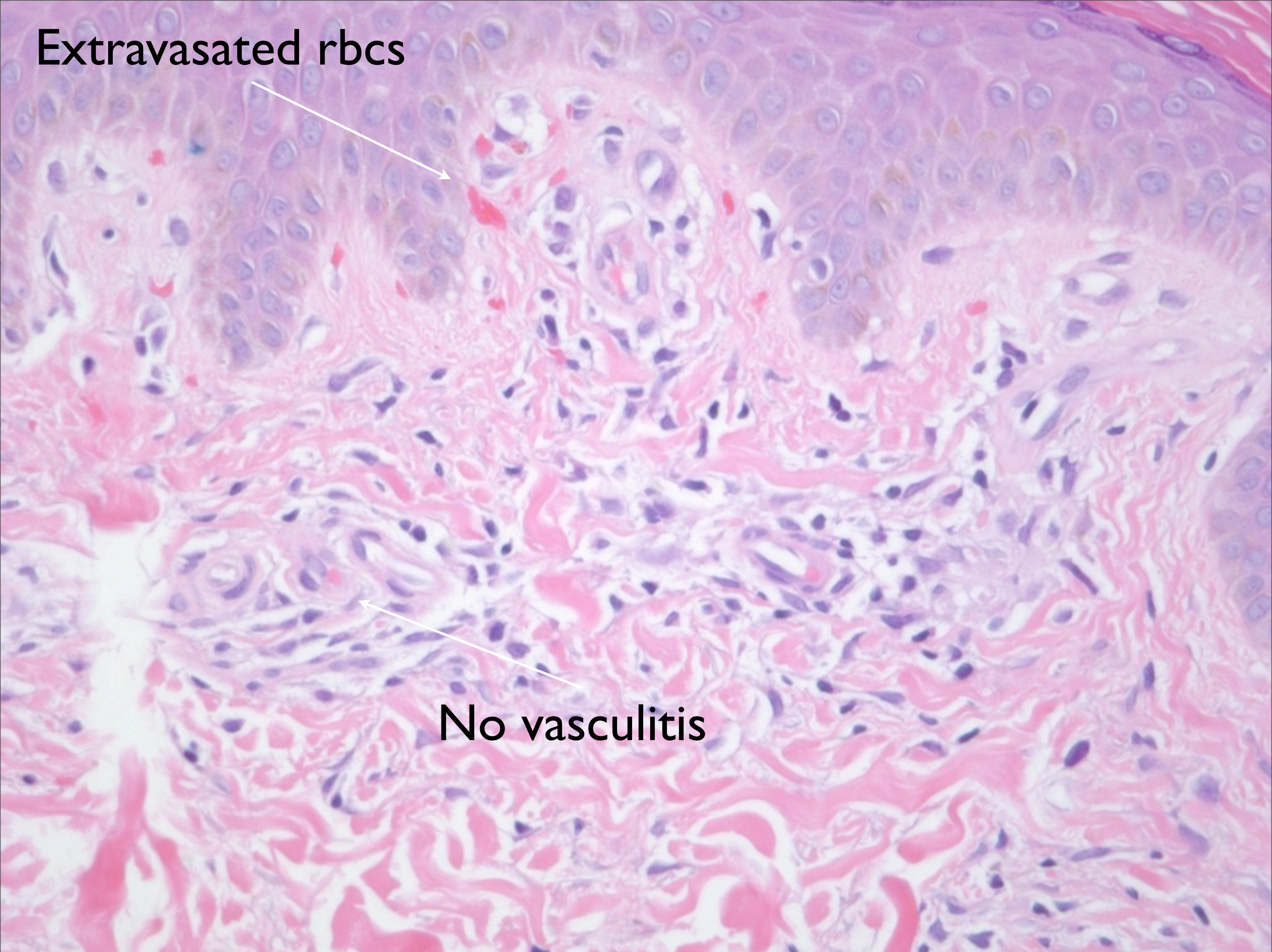
# What is the best diagnosis?

- Leukocytoclastic Vasculitis
- Pigmented Purpuric Dermatoses
- Post-inflammatory pigmentary alterations
- Macular amyloidosis
- Granuloma annulare

# Pigmented Purpuric Dermatosis



Extravasated rbcs



No vasculitis